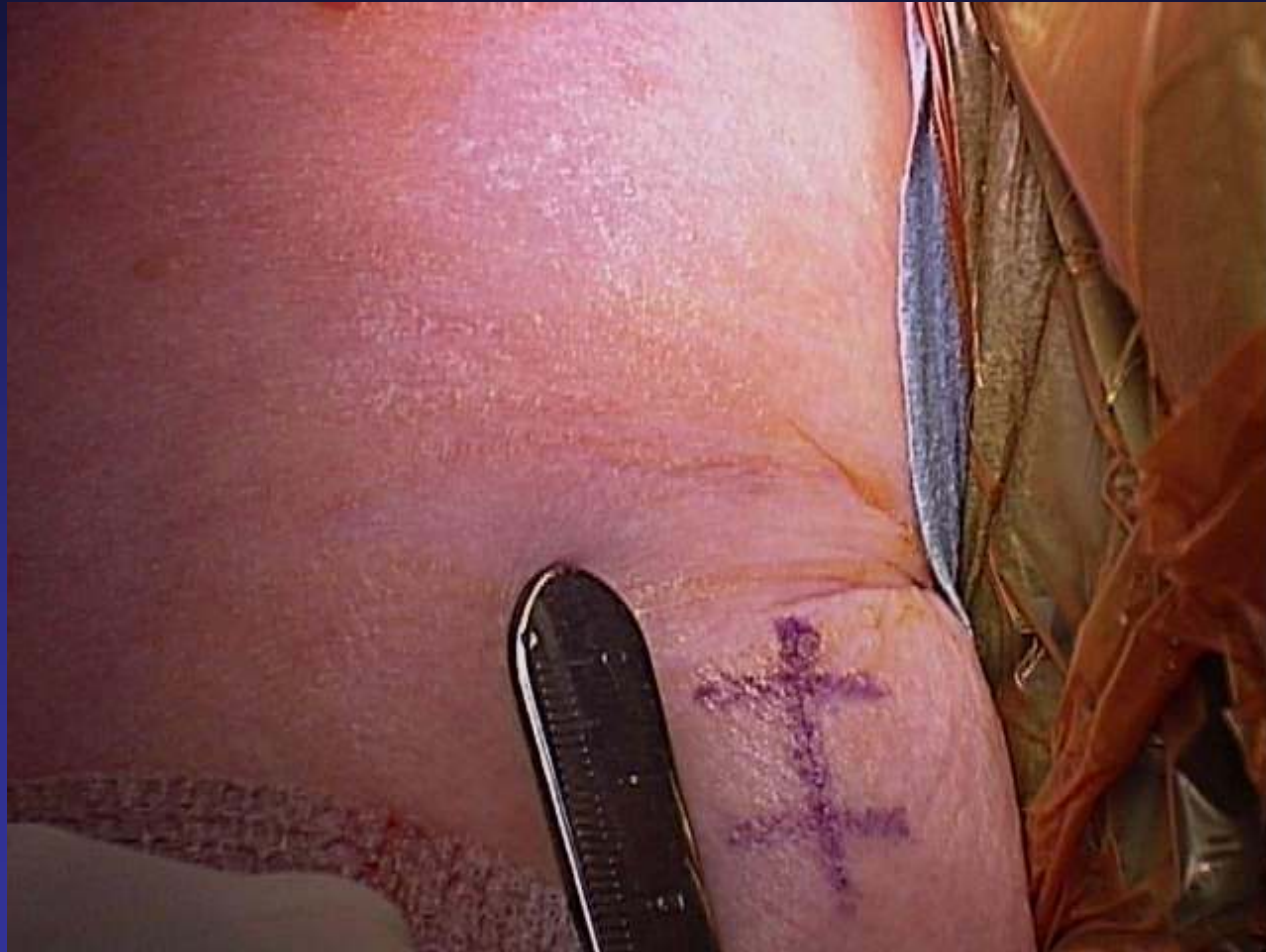

Surgical Treatment of Biceps Pain

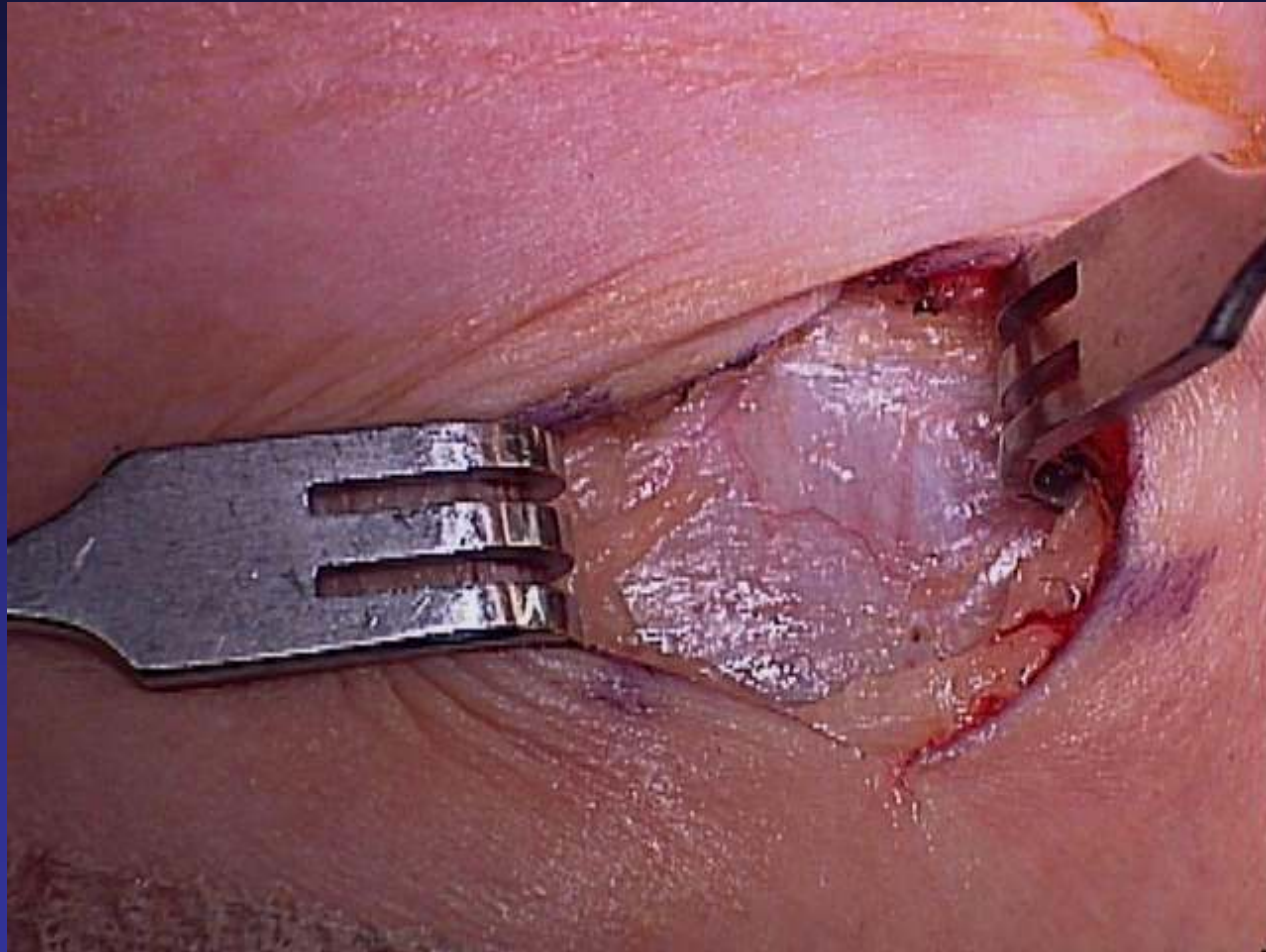
Pictorial of a Sub Pectoral Biceps Tenodesis



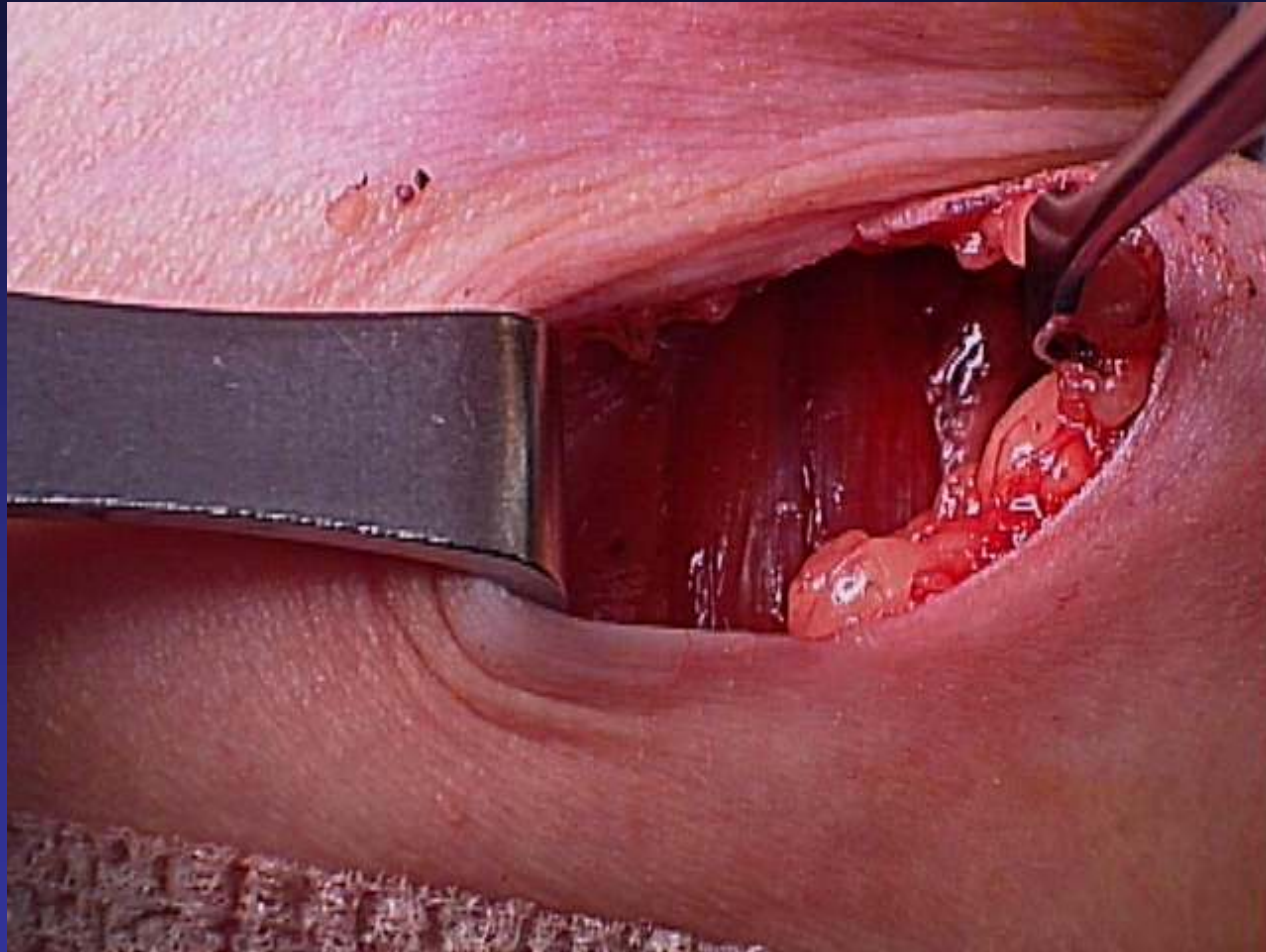
One Inch Skin Incision



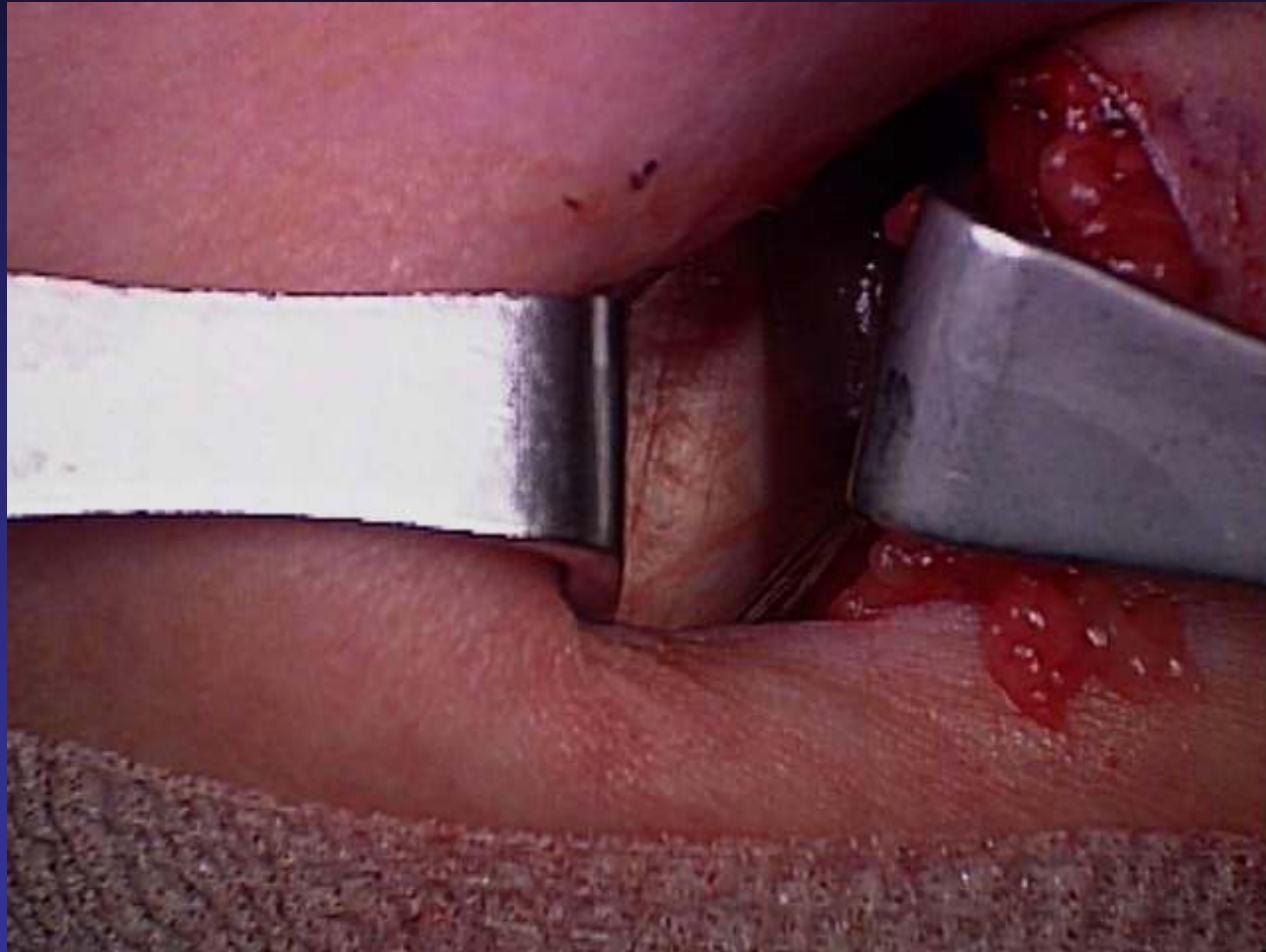
Superficial Fascia is Encountered & Incised



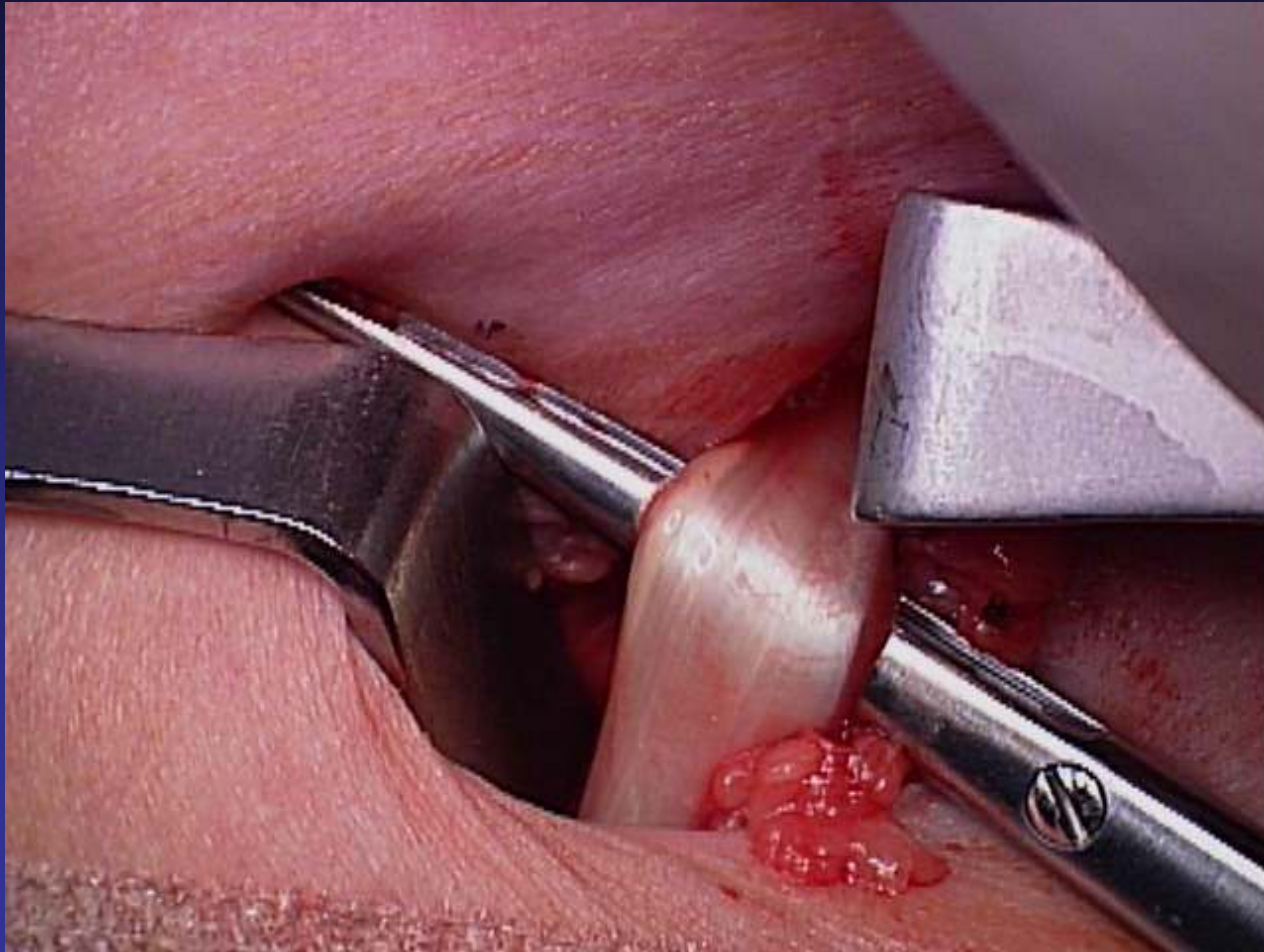
Muscles are Retracted to the Side
to Reveal the...



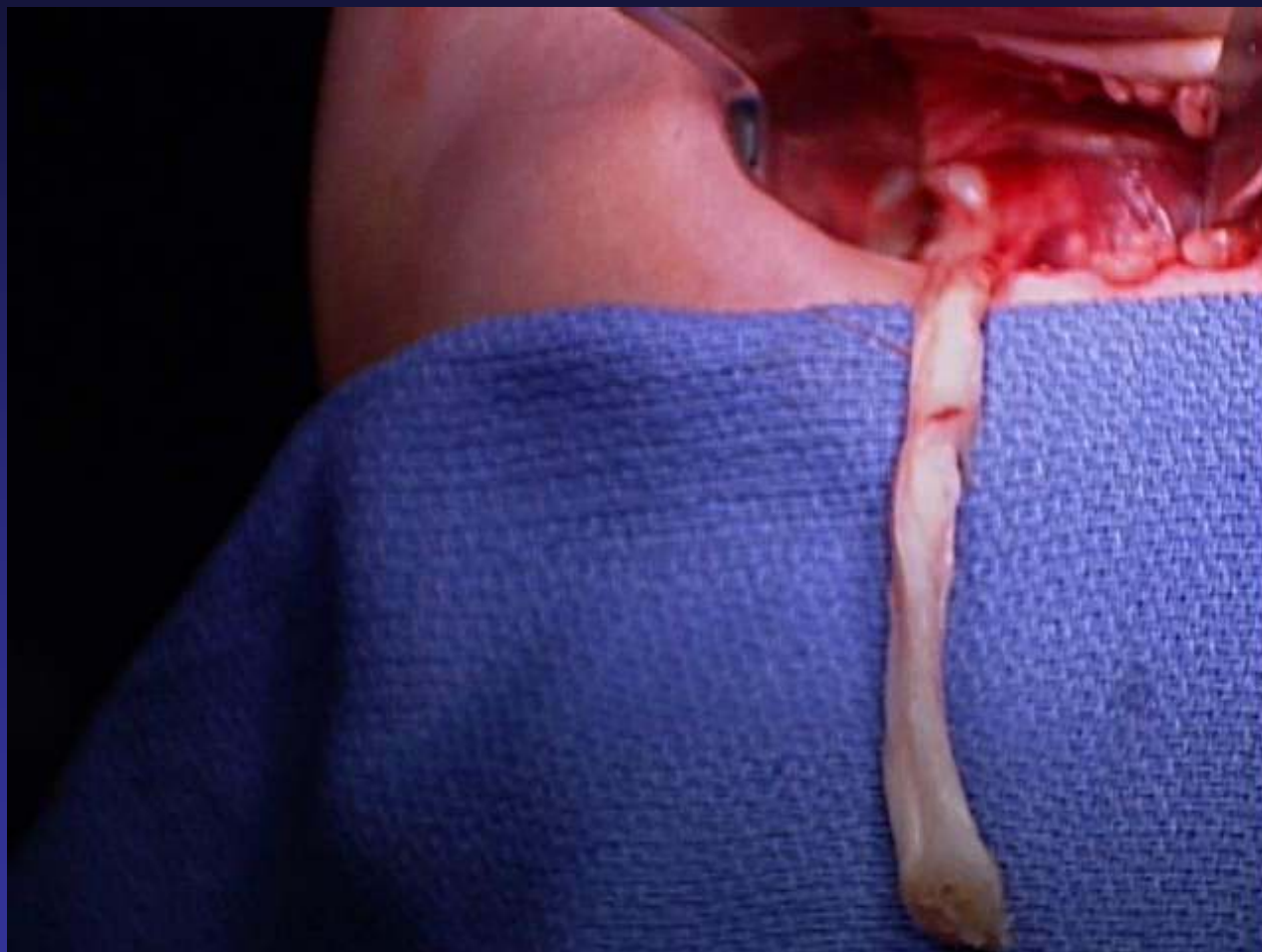
Long Head of the Biceps Tendon



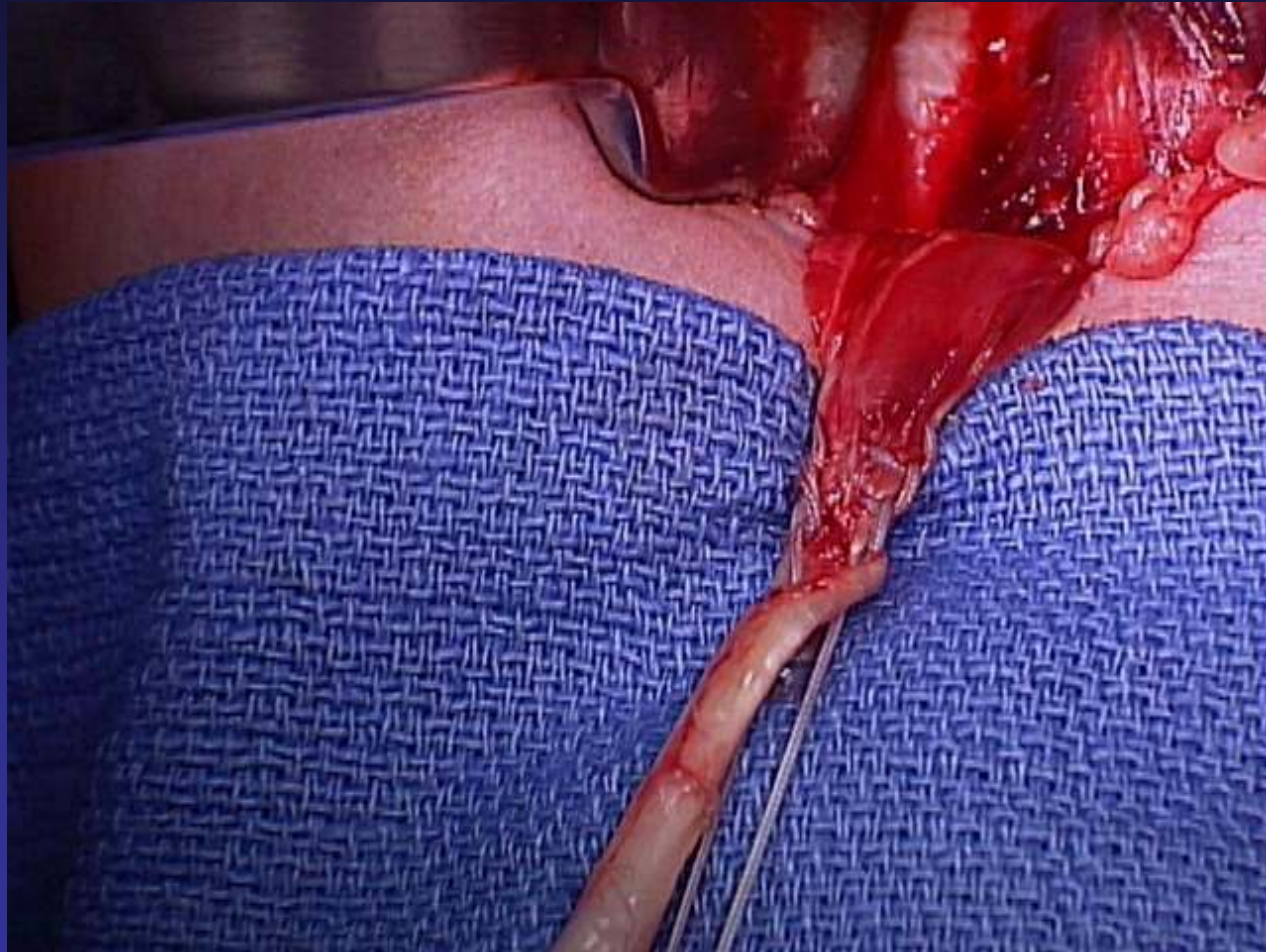
Delivering LHB Tendon



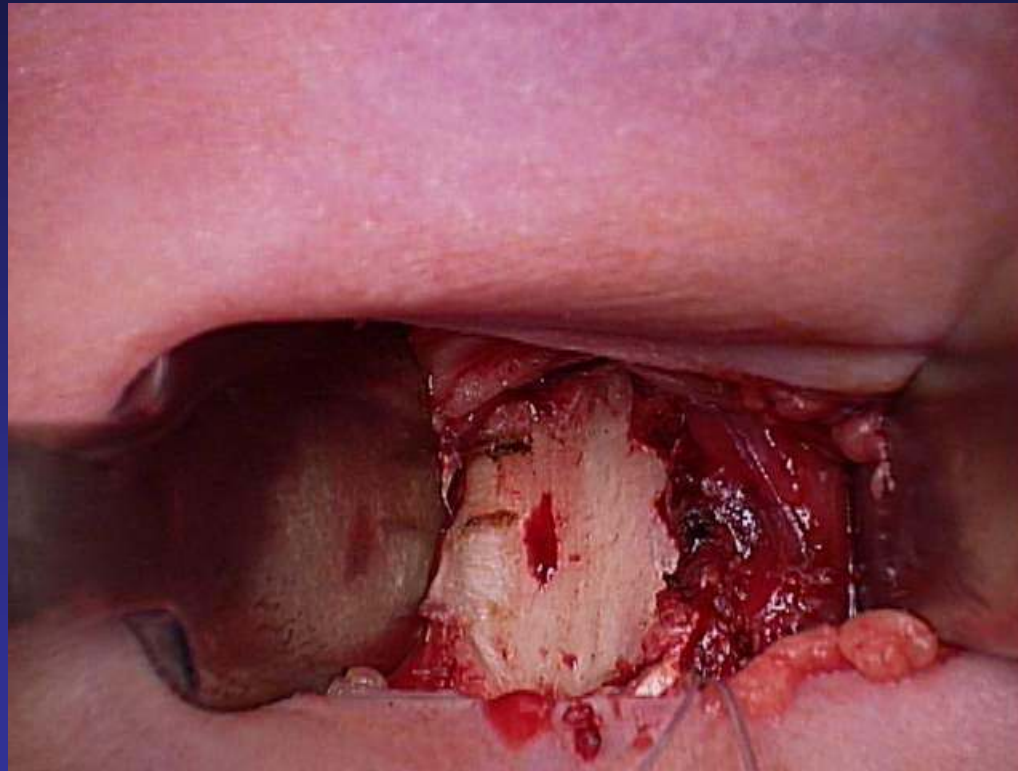
LHB Tendon



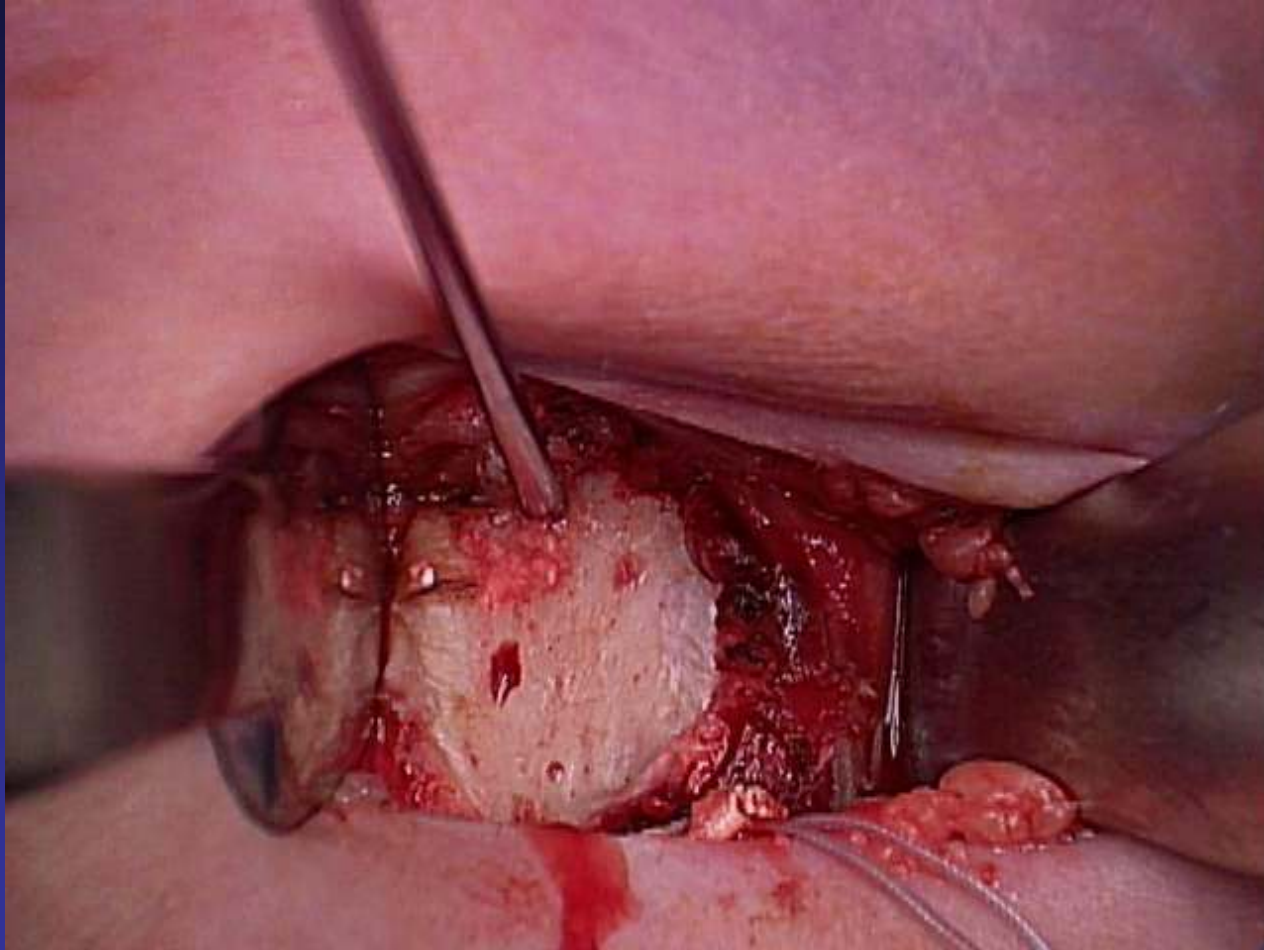
Stitches at the Musculotendinous Junction



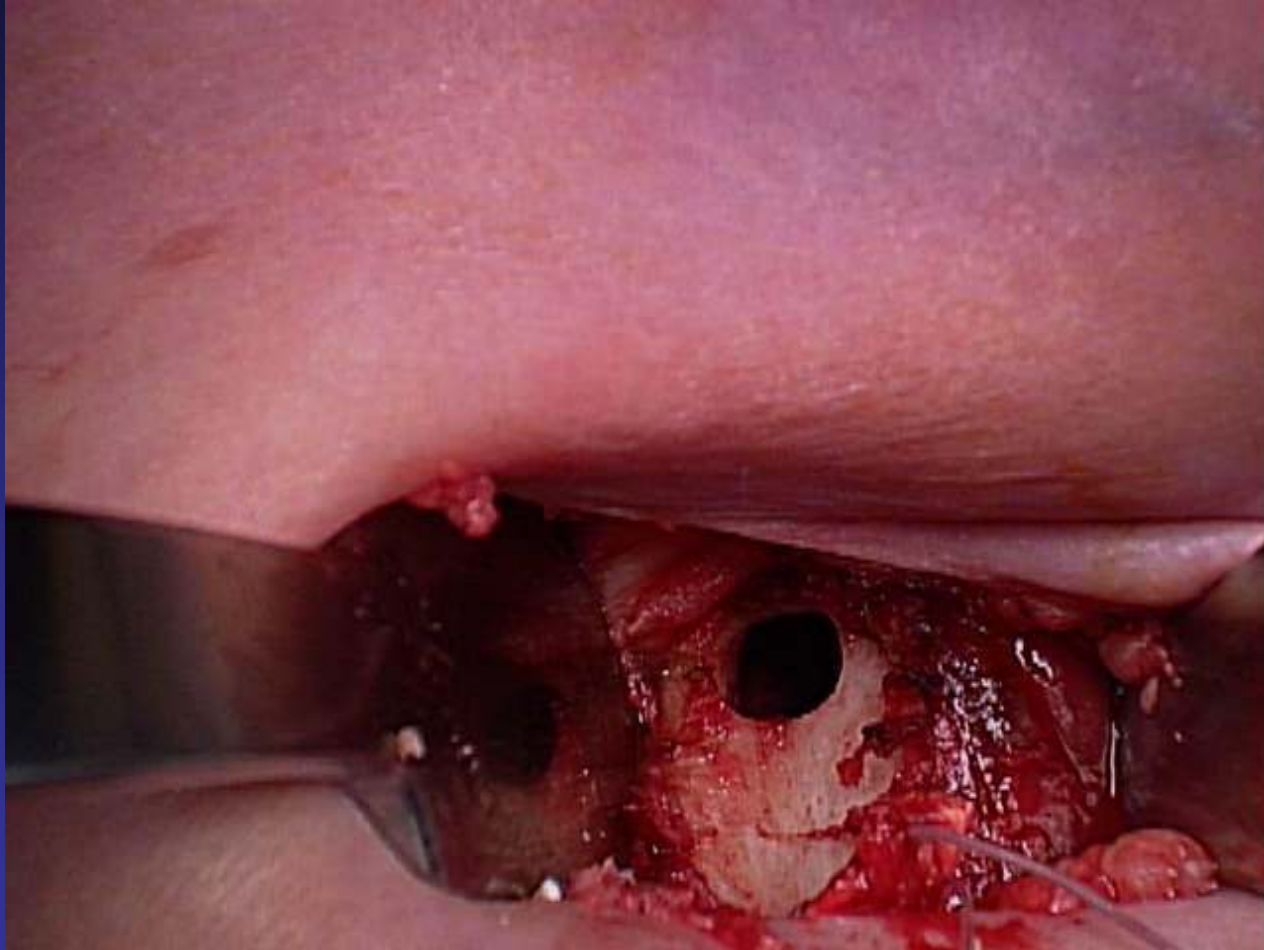
Intertubercular Groove on the Humerus



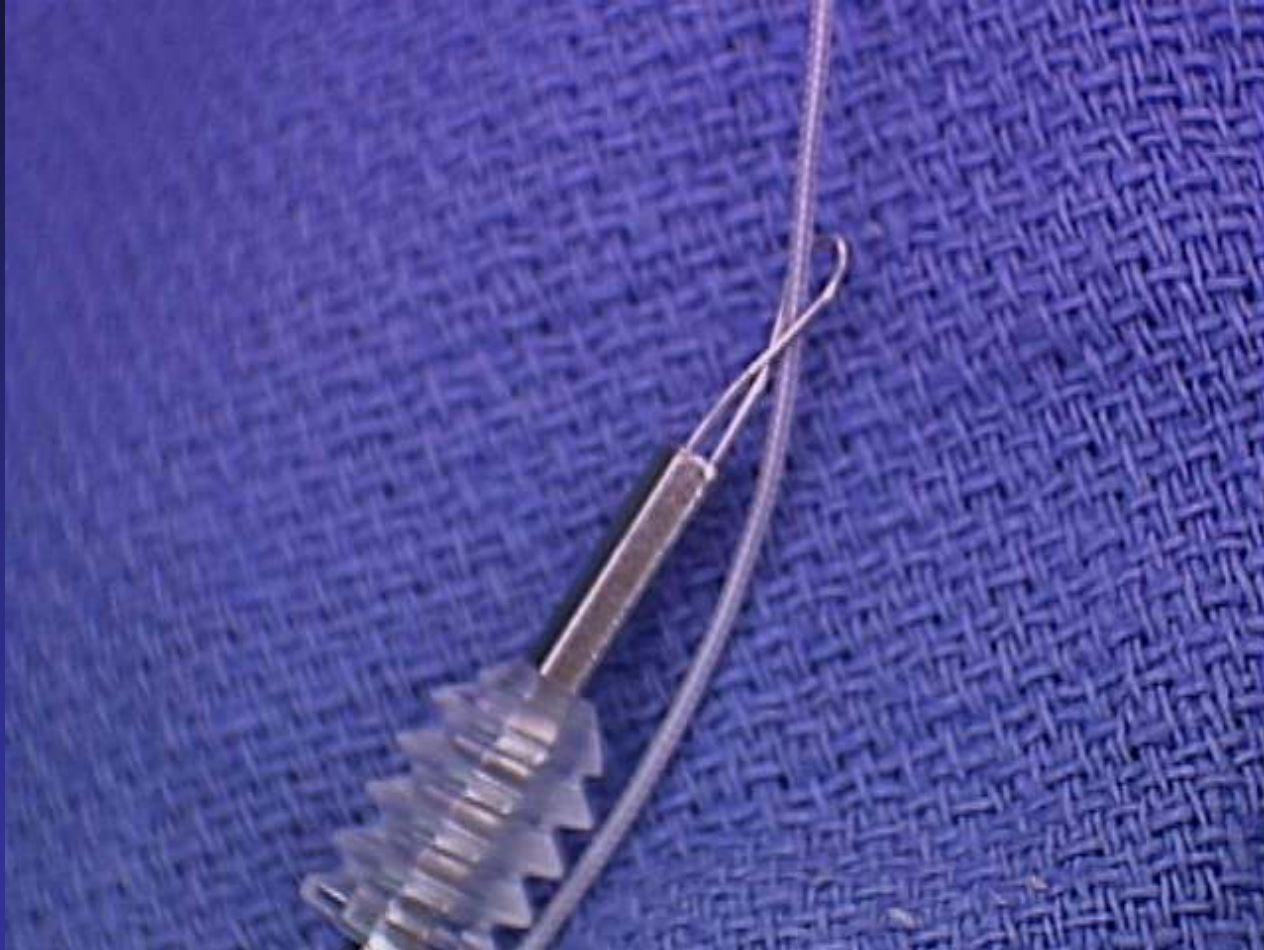Guide Pin in Bone



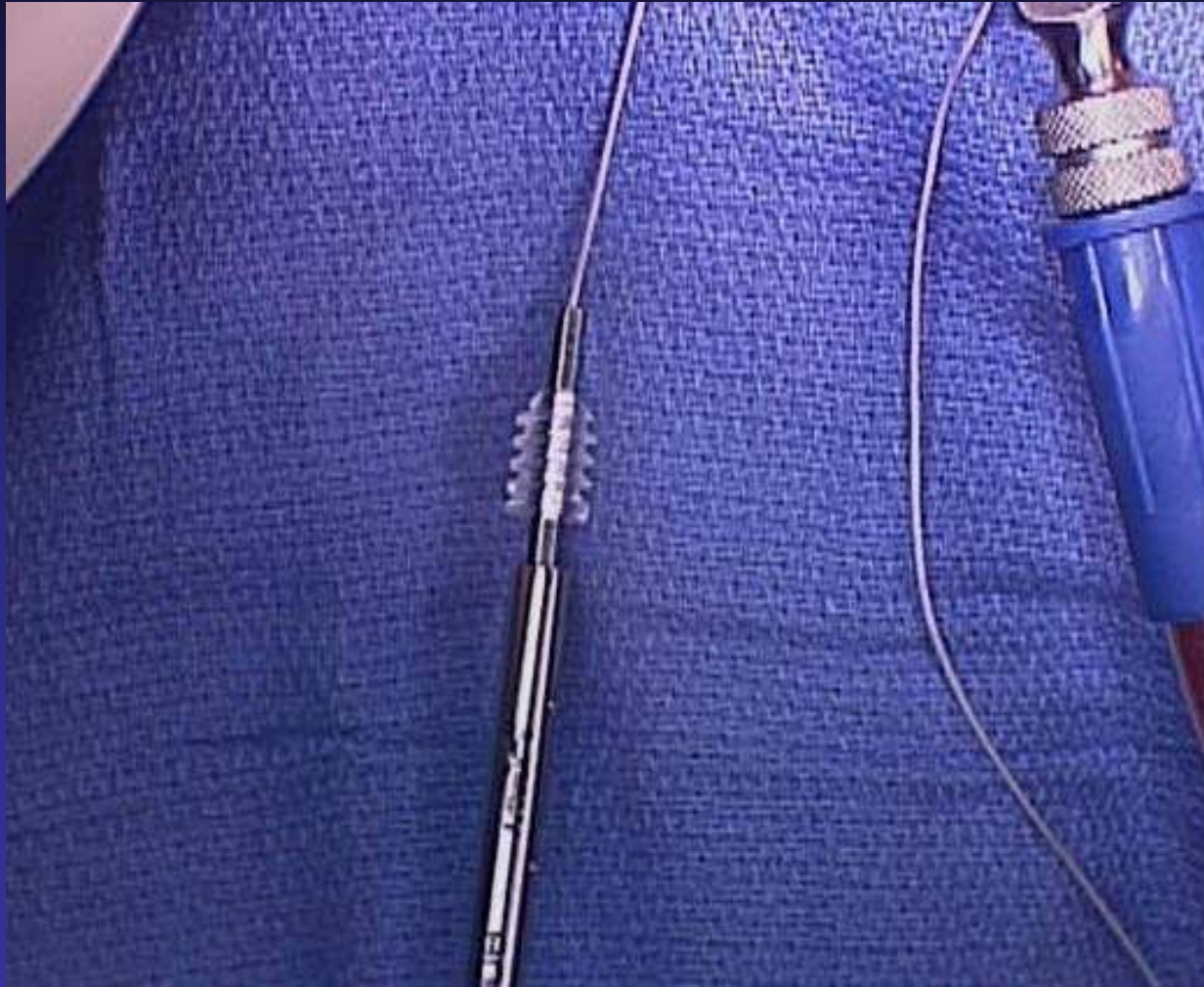
8mm Drill into the Bone



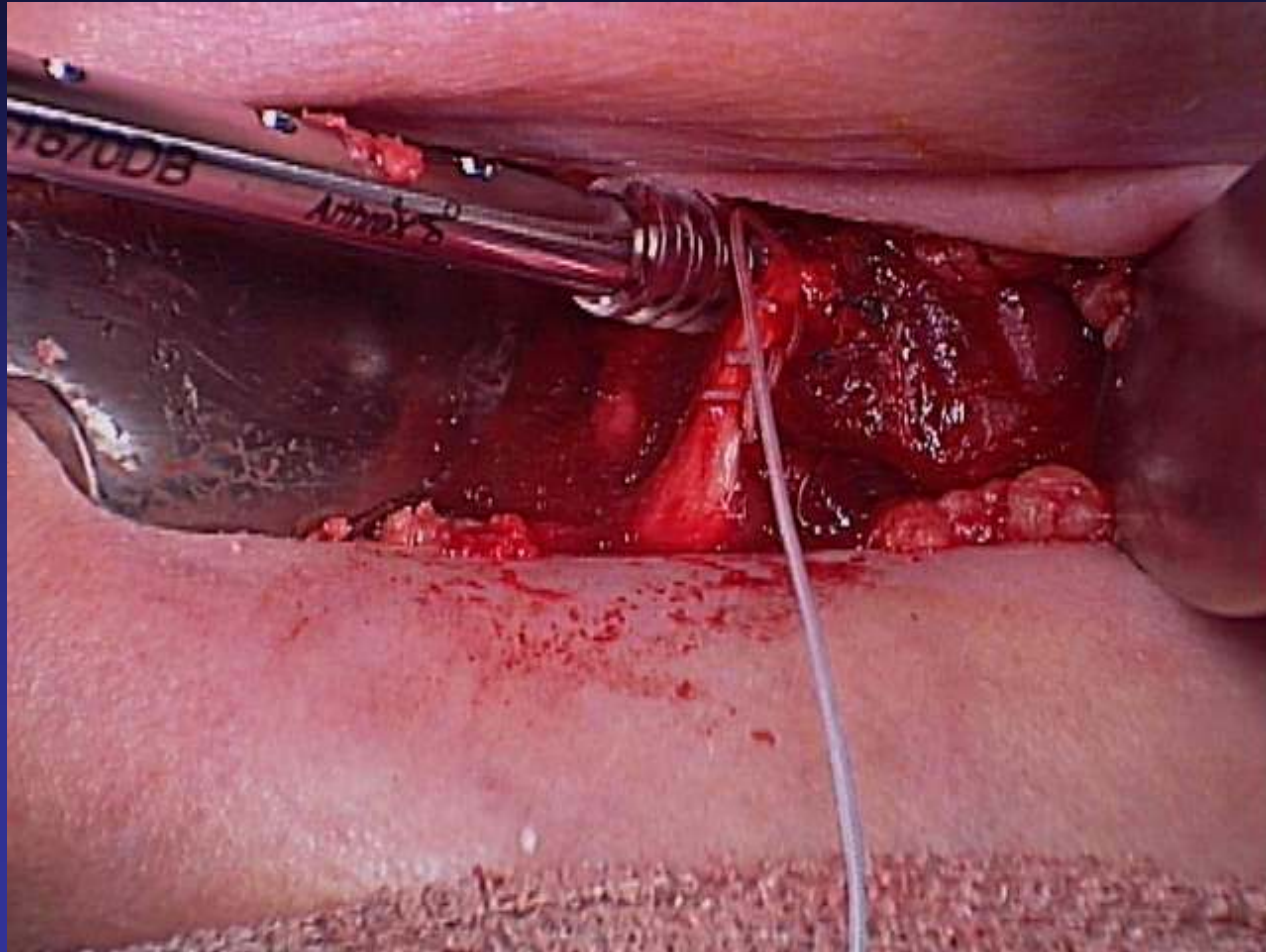
Shuttling Suture into Screwdriver



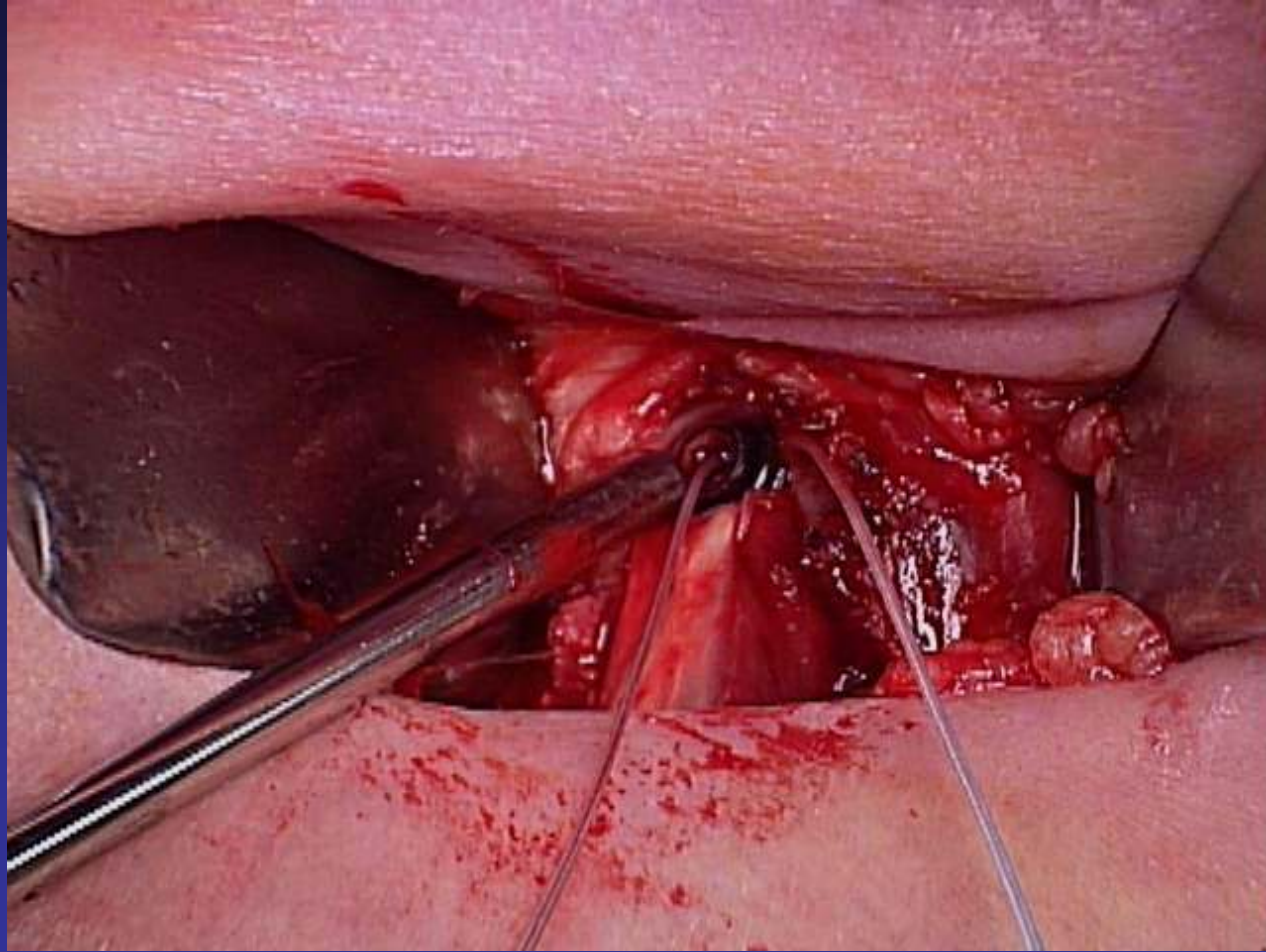
Suture in Screwdriver



Inserting Tendon & Screw into Bone



Screw & Tendon in the Bone



Final Look

